

Paraneoplastic hypoglycemia in gastric adenocarcinoma

조선대학교병원 내과¹, 조선대학교병원 혈액종양내과²

이한용¹, 이슬비², 박상곤²

Background: Paraneoplastic hypoglycemia is a rare phenomenon in malignancy characterized by repeated hypoglycemia. The mechanisms of hypoglycemia due to malignancy are diverse.

Case: A 38-year-old male patient had poorly differentiated adenocarcinoma of gastric body with multiple liver metastases. He showed repeated episodes of hypoglycemia. To evaluate the cause of recurrent hypoglycemia, a biopsy was performed on the liver metastases, and a adenocarcinoma with neuroendocrine tumor portion was identified. We hypothesized that the cause of hypoglycemia might be the insulin secretion from neuroendocrine tumors of metastatic lesions. The patient's insulin and c-peptide level was elevated. However, immunohistochemical staining for insulin stained negative in gastric carcinoma lesion and liver metastases. Insulin secretion and insulin receptor autoantibody was not confirmed in the gastric adenocarcinoma and metastatic lesions. Furthermore, secretion of other molecules related to glucose metabolism have not changed. In order to manage the recurrent hypoglycemia, parenteral nutrition and cytotoxic chemotherapy were started. Recurrent hypoglycemia gradually improved. But hypoglycemia started to occur again after 6 months. Several other mechanisms other than insulin secretion might have been involved in hypoglycemia.

Conclusion: We report the rare case of paraneoplastic hypoglycemia in gastric adenocarcinoma and would like to review the tumor induced hypoglycemia.

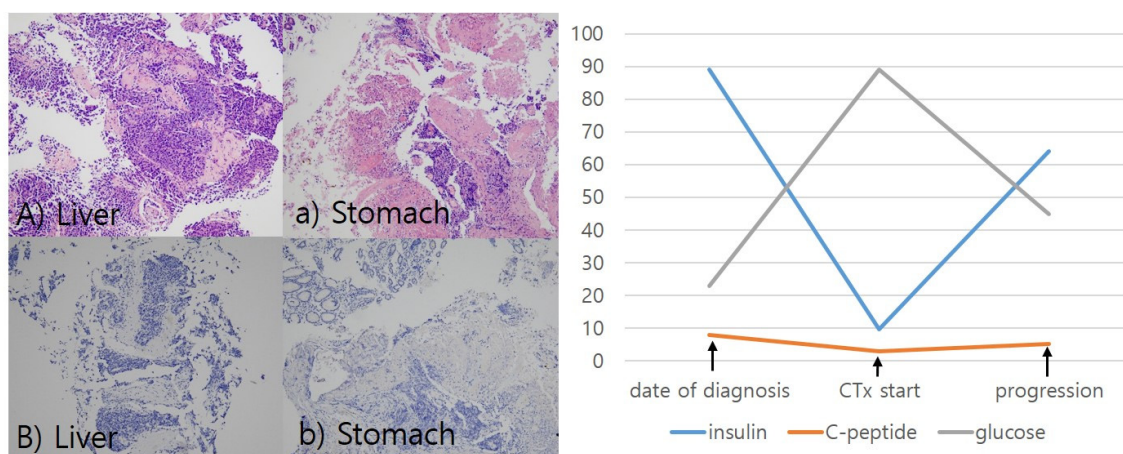


Figure. H-E staining Liver(fig. A), stomach(fig. a), insulin immunostaining liver(fig. B), stomach(fig. b).

Insulin immunostaining was negative in liver and stomach.

Table. At the time of diagnosis, insulin & c-peptide level was increased and gradually improved after cytotoxic chemotherapy started. As the cancer progressed, the hypoglycemia worsened again.