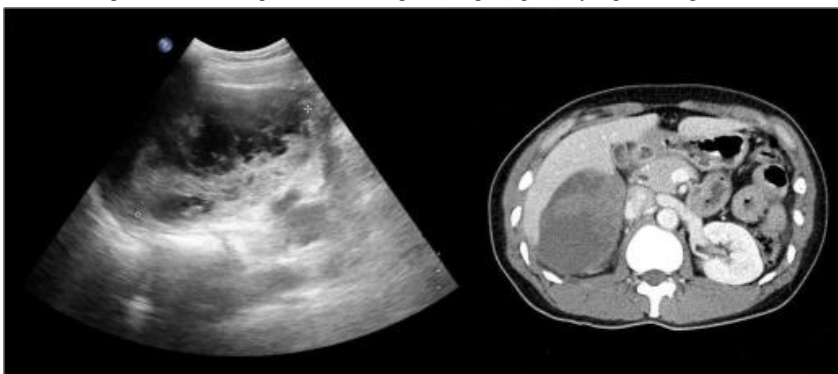


## ■ S-145 ■

## Spontaneous Rupture of Huge Subcapsular Hemorrhagic Hepatic Cyst

<sup>1</sup>Department of Internal Medicine, <sup>2</sup>Radiology, <sup>3</sup>Internal Medicine Dongguk University College of Medicine, Goyang, Korea\*Yun-Seong Kang<sup>1</sup>, Yun Jeong Lim<sup>1</sup>, Jae Hyun Kwon<sup>2</sup>, Hyoun Woo Kang<sup>3</sup>, Jae Hak Kim<sup>3</sup>, Jin Ho Lee<sup>3</sup>

Simple hepatic cyst is common benign lesion that occurs in 5% to 10% of the general population. Simple hepatic cyst is usually asymptomatic and requires no treatment. However, complication including intracystic hemorrhage, infection, intraperitoneal rupture, torsion, inflammation and obstructive jaundice can occur in about 10% and hemorrhage or infection are most common complications. Although spontaneous rupture occasionally occurs, cystic rupture into peritoneal cavity may be mainly caused by trauma. There is no standard strategy for management of hepatic cyst rupture. If acute pain develops, operation or percutaneous drainage are helpful. 37-year-old woman complained of acute severe right upper quadrant abdominal pain with no trauma history. Ultrasound and CT scan showed 12cm subcapsular cystic mass and hemorrhage into the peritoneum. She had no evidence of parasite infection and malignancy on the stool, serology and image. After percutaneous drainage of 8.5 French pigtail catheter, abdominal pain subsided and size of subcapsular cyst decreased into the 7cm on follow up image after drainage of dark blood. Here, we report a case of spontaneous subcapsular hemorrhage of huge hepatic cyst presenting with acute abdominal pain.



## ■ S-146 ■

## A case of autoimmune hepatitis associated with Sjogren's syndrome

경상대학교 의학전문대학원 내과학교실<sup>1</sup>, 영채내과<sup>2</sup>\*유동훈<sup>1</sup>, 안연정<sup>2</sup>, 최자윤<sup>1</sup>, 민현주<sup>1</sup>, 이상일<sup>1</sup>, 이옥재<sup>1</sup>

Autoimmune hepatitis is a chronic unresolving inflammation of the liver characterized by hypergammaglobulinemia, circulating auto-antibodies, and the presence of interface hepatitis and portal plasma cell infiltration on histological examination. It can be associated with numbers of other autoimmune diseases. Overlap syndromes of AIH with primary biliary cirrhosis or primary sclerosing cholangitis are frequent, however, Sjogren's syndrome is rarely associated with autoimmune hepatitis. We report an unusual case of autoimmune hepatitis associated with Sjogren's syndrome. A 56-year-old woman was admitted because of abnormal liver enzymes. She was not taking medications and not a drinker. Her laboratory tests showed negative viral hepatitis markers, increased serum IgG level, and positive anti-nuclear antibody. Based on characteristic clinical features, live histologic features, serology, positive Schirmer's test, and salivary scintigraph, the diagnosis of auto-immune hepatitis and Sjogren's syndrome were made. Her clinical symptoms and abnormality of liver test improved with prednisolone and azathioprine and she achieved complete remission.