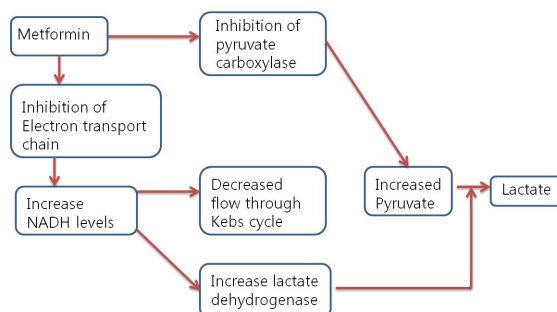


Case of Transient visual loss due to Metformin-associated metabolic acidosis(MALA)

충남대학교병원 신장내과

*전해원, 김해리, 함영록, 최대은, 나기량, 이강욱, 전재완

Although metformin has become a drug of choice for the treatment of type 2 diabetes mellitus, some patient may not receive it owing to the risk of lactic acidosis associated with a high rate of mortality of approximately 50 percent. We present a case of Metformin-associated lactic acidosis (MALA) resulting in transient visual loss. A 68-year-old man with type 2 diabetes mellitus for 20 year, hypertension developed life-threatening lactic acidosis during treatment with metformin 1000mg orally twice a day for type 2 diabetes. He presented to our emergency department with a 2day diarrhea, nausea, vomiting and weakness, dizziness and visual loss. He had documented normal renal function 4 months before this admission (BUN 18.9 mg/dL, Cr 0.97 mg/dL). Clinical examination showed man who was agitated and confused, with Glasgow Coma scale of 4/5/6. General examination was otherwise unremarkable. Soon after arrival, He was hypotensive with a blood pressure of 91/52mmHg. Laboratory investigations showed a life-threatening metabolic acidosis with pH of 6.78, bicarbonate 4mmol/L, anion gap 38mmol/L, and base excess -19.9mmol/L. The blood glucose was 65 and serum lactic Acid >11mmol/L. His renal function was markedly reduced.(BUN 36.9mg/mL, Cr 2.31mg/mL) compared 4month before. A urinary catheter yielded a large amount of urine, ruled out obstruction. He was treated vigorous hydration and sodium bicarbonate infusion, but metabolic acidosis was not corrected. Therefore, he performed hemodialysis once. After once dialysis treatment, his decreased vision was improved, severe acidosis resolved. His renal function has stabilized with a creatinine of 1.01mg/mL. He was discharged from the hospital no day 6 without any neurologic complication. This case a relatively rare, though important complication from metformin. It is crucial to maintain a high suspicion of this complication in the differential diagnosis at the earliest stage for patient with metabolic acidosis and history of metformin use. Severe MALA can be treated with renal replacement therapy and generally has a higher survival rate than other caused of severe lactic acidosis.



Diagnostic accuracy of IgH rearrangement, FDG-PET/CT and BM biopsy to detect BM involvement in DLBCL

화순 전남대학교 병원 혈액내과

*김미희, 정승연, 정성훈, 안서연, 이재중, 김형준

Background/Aims: Bone marrow involvement(BMI) has important clinical implication in diffuse large B cell lymphoma (DLBCL) as a component of staging and International Prognostic Index (IPI). This study investigated that 18F-FDG PET/CT and molecular analysis of monoclonal Immunoglobulin heavy chain (IgH) rearrangement could increase the diagnostic accuracy of BMI at the time of diagnosis in DLBCL. **Methods:** This observational study conducted in 100 patients with newly diagnosed DLBCL from Jan 2017 to May 2018 from single institution. The specimens for IgH rearrangement PCR were obtained by fine-needle aspiration and unilateral trephine biopsy. In addition, 18F-FDG PET/CT was classified into two patterns(focal vs diffuse) based on the type of bony FDG uptakes. The section specimens were reviewed by hematopathologists according to the WHO classification. **Results:** 53 patients were diagnosed with advanced stage and 9 patients(9%) were confirmed morphologic BMI(mBMI) by section biopsy. IgH monoclonality(IgH BMI) was detected in 17 patients(17%) and bony involvement on PET/CT(PET BMI) was observed in 16 patients(16%), respectively. All nine patients with mBMI were linked together with either IgH BMI or PET BMI. Of 17 patients with IgH BMI, 6 patients(35.2%) were concordant with mBMI. Overall diagnostic accuracy of IgH BMI for detection of mBMI was 86%, and it's sensitivity and specificity was 66.7% and 87.9% with 96.4% of negative predictive value(NPV), respectively. In addition, among the patients with PET BMI, 5 patients (31.3%, 5/16) were concordant with mBMI. PET/CT assessment showed 85% of diagnostic accuracy with 55.6% of sensitivity, 87.9% of specificity and 95.2% of NPV, respectively. However, the combination of IgH rearrangement with PET/CT assessment resulted in 100% of sensitivity and 79.1% of specificity with 100% of NPV, respectively. Total 28 patients had positive results either IgH rearrangement or PET BMI. 11 patients showed only PET BMI, and another 12 showed only IgH BMI. **Conclusions:** Each PET/CT and IgH rearrangement was associated with low sensitivity and high NPV for detecting mBMI. However, combined evaluation could give more information to predict bone marrow involvement of DLBCL

Assessment parameter	Sn(%)	Sp(%)	PPV(%)	NPV(%)	Area under ROC curves	95%CI	P value
IgH PCR	66.7	87.9	35.3	96.4	0.773	0.585-0.960	0.007
PET/CT	55.6	87.9	31.3	95.2	0.717	0.515-0.920	0.032
IgH PCR or PET/CT	100.0	79.1	32.1	100.0	0.896	0.831-0.960	<0.001

Abbreviations: Sn, sensitivity; Sp, specificity; PPV, positive predictive value, NPV, negative predictive value