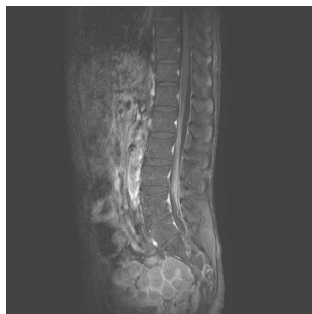


## Coinfection of central nervous system by MAC and CMV in a HIV-infected patient

분당서울대학교병원 내과

\*김민철, 김민석, 서준원, 전준영, 이지윤, 문송미, 송경호, 김홍빈, 김의석

**Introduction:** Mycobacterium avium complex (MAC) and Cytomegalovirus (CMV) are common opportunistic pathogens in Human immunodeficiency virus (HIV)-infected patients, but central nervous system (CNS) involvement is rare. We report a case of HIV-infected patient who developed polyradiculitis and meningitis due to simultaneous MAC and CMV infection. **Case description:** A 44 year-old bisexual HIV-infected man on antiretroviral therapy (ART) for 3 weeks presented paresthesia and progressive bilateral weakness of lower extremities, urinary retention and fecal incontinence that started six days ago. He had already been diagnosed with disseminated MAC infection and had taken clarithromycin for 2 weeks. His initial CD4+ cell count was 3/μl and plasma HIV viral load was 34,635 copies/ml. The spine MRI showed enhancement of filum terminale and meningeal enhancement from T11 level to sacral area. CSF profile showed WBC, 980 cells/mm<sup>3</sup>; protein, 778.5 mg/dl; and glucose, 24 mg/dl. CMV PCR was positive and MAC was isolated from CSF. Ethambutol and rifabutin and ganciclovir were added for MAC meningitis and CMV infection, respectively. In addition, methylprednisolone was given at 1 mg/kg in consideration of the possibility of MAC-related immune reconstitution inflammatory syndrome (IRIS). Follow-up MRI after 3 weeks showed a slight decrease in enhancement of the lesion. His paraplegia recovered enough to walk with assistance after 5 months. However, intraperitoneal lymphoma was diagnosed and chemotherapy was started. **Discussion.** CNS MAC infection is rare and prognosis is poor. MAC-related IRIS is usually self-limiting, but is hard to distinguish from active infection. Most previous cases of MAC-related IRIS occurred 5 to 10 months after the commencement of ART. Polyradiculopathy due to CMV infection is also rare and only a few cases are reported. No coinfection of MAC-CMV in CNS has been reported yet. **Conclusion:** In HIV-infected patients, neurological symptoms at spinal cord level may be a sign of opportunistic infection by multiple microorganisms and IRIS can develop during ART. Rapid diagnosis and treatment should be warranted to minimize neurological damage and improve the prognosis.



## HFRS combined with community-acquired Pseudomonas aeruginosa bacteremia in previously healthy adult

<sup>1</sup>가톨릭대학교 의과대학 내과학교실 감염내과, <sup>2</sup>건양대학교병원 응급의료센터

\*구현담<sup>1</sup>, 정형석<sup>2</sup>, 이래석<sup>1</sup>, 최수미<sup>1</sup>

Hemorrhagic fever with renal syndrome (HFRS) has become an important public health issue because of the increasing incidence and should not be excluded in patients who have no travel history to risk area, especially from October to December in Korea. Pseudomonas aeruginosa is a well-known nosocomial pathogen in patients with underlying diseases. However, it can also affect healthy people in communities. Here, we report the first case of HFRS and community-acquired P. aeruginosa bacteremia in previously healthy adult. A 65-year-old man came to the emergency room (ER) on December 20, 2017 due to temporary loss of consciousness. Also, he complained fever, chills, myalgia for several days. He was a pharmacist living in Seoul and had no recent travel history. At ER, blood pressure was 107/65 mmHg, heart rate was 80 beats/min, and temperature was 39.1°C. He was mild confused. Forty-two hours after admission, sudden hypotension developed with mental deterioration. Chest X-ray revealed bilateral infiltrates suggesting pulmonary hemorrhage and edema. Encephalitis was suspected due to seizure episode and generalized slow waves on electroencephalography. Laboratory findings showed renal insufficiency, thrombocytopenia and elevation of aspartate aminotransferase and alanine aminotransferase. P. aeruginosa were cultured in the blood collected at the time of shock. Antibody against Hantavirus was seroconverted on follow-up by indirect immunofluorescent assay on the 21th hospital day (HD). Antibiotics (piperacillin/tazobactam and amikacin), anti-convulsants and supportive care including renal replacement therapy, mechanical ventilation were provided as shown in figure. After the 18th HD, the patient recovered from oliguria and developed polyuria from the 32th HD. His mental status gradually recovered to almost normal (GCS score 14) on the 20th HD and he was discharged at the 45th HD. His kidney function became normalized three months after the onset.

