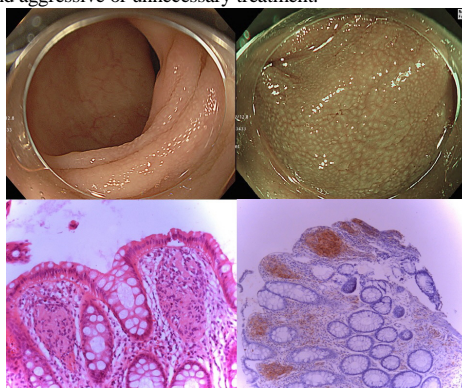


## A case of Mucosal schwann cell hamartoma

가톨릭대학교 의과대학 여의도성모병원 소화기내과

\*강경민, 정대영, 김진일, 문준기, 나재원

**Introduction:** Mucosal schwann cell hamartoma(MSCH) is benign neuronal polyp in colorectum purely. composed of S-100-positive Schwann cells, which first proposed in 2009 to avoid confusion with the neural lesions that have significant associations with inherited syndromes. MSCH is a very rare disease, but it is important to distinguish it from other diseases with similar feature, so we will discuss this case. **Case:** A 47-year-old man visited our hospital for regular check up. He had no underlying medical diseases, and any other family history and symptoms. colonoscopy showed loss of vascular pattern and mild edematous tiny nodularitic (like villi) mucosal change at distal sigmoid colon(AV 20cm), then biopsy was done. On microscopic immunochemistry, S-100 protein positive findings were observed and follow up colonoscopy was performed. Endoscopy showed non specific mucosal change in whole rectum: Exaggerated crypt epithelium makes fine white granular pattern. On HD-NBI view, surface looks like white opaque substance with regular honey comb pattern. The biopsy revealed S-100 positive in schwann cells, so Mucosal schwann cell hamartoma was diagnosed. Since it was benign tumor, no further treatment was performed and planed regular follow up. Discussion This case is an example of a MSCH diagnosed incidentally on a regular check up in a patient with no symptoms. A diagnosis of MSCH should be made after exclusion of other lesions that resemble spindle cell proliferation and other neuronal tumors. The ability to distinguish a GIST from a Schwann cell hamartoma is critical because, unlike neural tumors, GISTs have malignant potential. In fact, MSCH is easy to overlook as a rare lesion, but it is important to include it in differential diagnosis of S-100 positive spindle cell proliferative lesions to prevent accurate diagnosis and aggressive or unnecessary treatment.



## A rare case of appendiceal Dieulafoy's lesion bleeding

명지병원

\*서혁, 은종렬

**Introduction** The annual incidence of lower gastrointestinal bleeding (LGIB) is approximately 0.03% in the adult population, around 80% of which are in the colorectum. Appendiceal hemorrhage is an extremely rare cause of LGIB, with few cases reported in the scientific literature. Bleeding due to Dieulafoy lesion is also rare cause of 1-2% of acute gastrointestinal bleeding. The stomach is the most common location of Dieulafoy lesion bleeding, accounting for approximately 71% of the cases and only 2% in the colon. We present a rare case of appendiceal Dieulafoy lesion bleeding diagnosed as colonoscopy and treated with laparoscopic appendectomy. **CASE** A 40-year-old man without a medical history was rushed to the emergency room complaining of hematochezia. He was suspected of acute diverticular bleeding by computed tomogram. At the time of admission, the vital signs were stable but hemoglobin level was maintained by packed RBC transfusion (2pints) for the night. Colonoscopy was performed on the next day. Large amount of old and fresh mixed blood was accumulated in the whole colon, and fresh blood in the cecum. When cecum base was washed out, active oozing bleeding was observed from the orifice of appendix. No other hemorrhagic focus was seen in the remained colon. During several minutes of observation and washing, active bleeding persisted and the patient was consulted to the surgeon. He underwent a laparoscopic partial cecectomy immediately, and no more bleeding occurred. The resection specimen showed Dieulafoy lesion (arrow in Fig. 3). **Conclusion** Appendix is rare location in LGIB. Few cases of appendiceal Dieulafoy lesion bleeding was reported. In this case, we detected appendiceal hemorrhage by colonoscopy and treated by laparoscopic appendectomy.

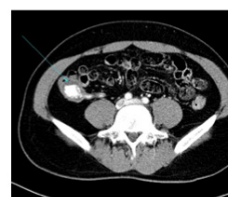

Fig. 1. CT scan showed dye extravasation in the cecum.

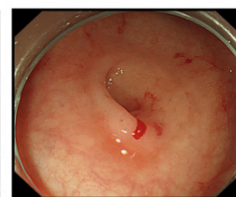


Fig 2A. The appendiceal orifice: just after the washing.

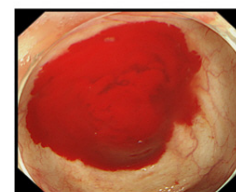
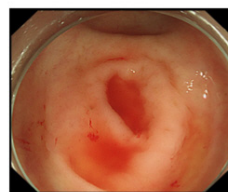
Fig 2B. Active oozing bleeding was observed from the appendiceal orifice.

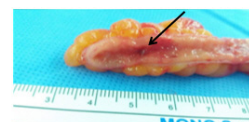
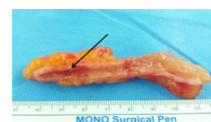


Fig 3. Dieulafoy lesion was confirmed after the surgery (black arrow).