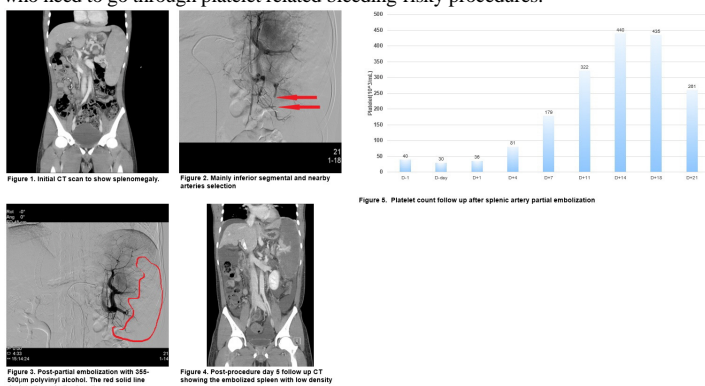


A case of thrombocytopenia overcome by splenic artery partial embolization

건양대학교병원 내과

*나종현, 이태희, 강영우, 최용우, 허규찬, 김선문, 송경호, 구훈섭, 류기현

INTRODUCTION: In splenomegaly, especially in cirrhotic liver with portal hypertension, thrombocytopenia is a common hematologic abnormality, which is because the enlarged spleen can hold circulating platelet mass sequestered. Splenomegaly does not usually bring down platelet count less than 50,000/mL, and it is not an actual problem unless complicated by coexisting coagulopathy. However, it can still cause bleeding problems with patients who need to undergo bleeding-risky procedures. This case shows the medical splenectomy by partial embolization of splenic artery can bring up the platelet count in patients with splenomegaly. **CASE:** A 23-year old male with cryptogenic liver cirrhosis came in again due to esophageal varices bleeding. He has been through numerous endoscopic bleeding controls and prophylactic varices ligations since he had first hematemesis 5 years ago. He had TIPS procedure, which did not conclusionally reduce his portal hypertension and repetitive varices bleedings. To help his repetitive bleedings and dental treatments, medical splenectomy was chosen as a management of thrombocytopenia. Procedure was successfully done and platelet counts kept rising, then sustained within normal limits for a while. The lab follow up is still in the process. **DISCUSSION:** Even if splenomegaly-induced platelet sequestration resolves by such procedure, thrombopoietin-related thrombocytopenia still can take place in cirrhotic liver patients, which is common cause of splenomegaly. Long term platelet count follow up is necessary. To be specific for the case, it is also uncertain that the resection of spleen, surgical or medical, could help stopping varices bleeding since the key to the prevention lies on controlling portal hypertension rather than thrombocytopenia. Even with the limitations, the procedure itself has proven, in short term manner, that thrombocytopenia could be relaxed and could help patients who need to go through platelet related bleeding-risky procedures.



Clinical Features and Outcomes of Epstein-Barr Viral Hepatitis

단국대학교 의과대학 내과학교실

*남윤권, 남광우, 방기배, 최준호, 신현덕, 김석배, 신정은, 김홍자, 송일한

Background/Aims: We infrequently encounter the patients with acute hepatitis caused by Epstein-Barr virus. But the clinical characteristics and courses of the EBV hepatitis was still not evaluated clearly because of the low frequency and mild severity. We aimed to know the clinical features and outcomes of EBV hepatitis. **Methods:** From January 2008 to December 2017, 41 patients who diagnosed as EBV hepatitis were enrolled. The diagnosis of EBV hepatitis was following: 1) Detection of EBV from patient's blood by PCR or positive viral capsid antigen Ig M. 2) No evidence of hepatitis such as other viral hepatitis, toxic hepatitis, autoimmune hepatitis and ischemic hepatitis. 3) Liver enzyme elevation above normal limit. We retrospectively collected the data of clinical manifestations, laboratory results and clinical course. **Results:** Total 41 patients were enrolled which is consisted of 22 male patients (53.7%) and 19 female patients (46.3%). Their mean age was 44.9 ± 19.0 (17-82 years). Fever (19.5%) was the most common chief complaint followed by sore throat (17.1%), abdominal pain (12.2%), LFT elevation (12.2%). 27 patients took abdominal radiologic examinations and 26 patients (95.8%) showed splenomegaly (44.4%), lymphadenopathy (37.0%), hepatomegaly (25.9%), fatty liver (18.5%), periportal edema (18.5%). Initial AST, ALT were 452.9 ± 571.1 IU/L, 417.9 ± 627.7 IU/L and then gradually decreased to 39.2 ± 11.9 IU/L, 45.4 ± 8.5 IU/L with conservative treatment after 21 days. AST and ALT normalization rate showed 73.2% and 53.7% at 21 days, respectively. All patients except for 1 patient who expired discharged without specific complications. **Conclusions:** EBV hepatitis should be considered if elevated LFT associated with fever, sore throat and lymphadenopathy. EBV hepatitis is usually mild and resolves without serious complications even with conservative treatment

